

Maxillary Expansion and Protraction Using Mini-Implants and the Benefit Direct Mechanism

BENEDICT WILMES, DMD, MSD, PhD

KATHRIN BECKER, DDS, PhD

JAN WILLMANN, DDS, DMD

NOUR E. TARRAF, BDS, MSDc, MRACDS, MOrth RCS

DIETER DRESCHER, DDS, MSC, PhD

Maxillary deficiency is a common orthodontic problem frequently found in Class III patients. A transverse deficiency is often associated with unilateral or bilateral posterior crossbite,¹ while an anteroposterior deficiency can be associated with an anterior crossbite or edge-to-edge relationship.²

Rapid maxillary expansion has long been considered the optimal treatment for transverse maxillary deficiency³⁻⁵; combined with a protraction facemask, it stimulates downward and forward growth of the maxilla while redirecting mandibular growth downward and backward.⁶⁻⁸ Conventional toothborne expansion and protraction appliances produce many undesirable dental side effects, however, such as buccal tipping, root resorption, reduced buccal bone thickness, and dehiscence and gingival recession, usually resulting from the heavy forces required.⁹⁻¹⁴ Protraction forces from the facemask can also lead to mesial migration of the dentition and anterior crowding.⁶

Mini-implants have recently been used to share the load of expansion and protraction and thus avoid unwanted side effects. In 2007, Wilmes and colleagues introduced the Hybrid Hyrax* expander, which is anchored by two mini-implants

in the anterior palate and two molar bands (Fig. 1).¹⁵⁻¹⁷ Similar hybrid expanders, called miniscrew-assisted rapid palatal expanders (MARPE), were subsequently described by Garib and colleagues,¹⁸ Lee and colleagues,¹⁹ and Moon and colleagues.²⁰ Miniscrew-supported expanders can be effective when used in growing Class III patients,^{6,21-27} allowing skeletal maxillary protraction without the common dental side effects.^{19,23,24,28} Miniplates offer an alternative to facemasks, enabling full-time wear of protraction elastics and better vertical control of the mandibular arch, as well as improved patient acceptance. In addition, the use of the alternate rapid maxillary expansion and constriction (Alt-RAMEC)^{27,29} technique over a nine-week period can enhance the response of the maxilla to the protraction forces and produce good results in children with more sutural maturation.³⁰⁻³²



Dr. Wilmes



Dr. Becker



Dr. Willmann



Dr. Tarraf



Dr. Drescher

Dr. Wilmes is a Professor, Dr. Becker is a Research Associate, and Dr. Drescher is a Professor and Head, Department of Orthodontics, University of Düsseldorf, Moorenstrasse 5, 40225 Düsseldorf, Germany. Dr. Willmann is in the private practice of orthodontics in Duisburg, Germany. Dr. Tarraf is a Professor, University of Sydney, Australia, and in the private practice of orthodontics in Sydney. E-mail Dr. Wilmes at wilmes@med.uni-duesseldorf.de.



Fig. 1 Hybrid Hyrax* for rapid maxillary expansion with anchorage from two mini-implants and two molar bands.

KRAVITZ KEYS

- This article introduces Benefit Direct** rings, which are threaded extensions from a Hybrid Hyrax frame.
- Benefit Direct mini-implants engage the threaded rings.
- Together, they allow for an “appliance-first” method of Hybrid Hyrax placement.
- Coupling of the mini-implant with the appliance is tight even if the insertion angle is not perfect.

To ensure stability and reliability of the mini-implants, they should be placed in areas with the best quality of cortical bone. Several cone-beam computed tomography (CBCT) studies have found the best bone to be located in the anterior palate, in an area called the T-Zone.³³⁻³⁵ With the original Hybrid Hyrax, the mini-implants were placed paramedian to the anterior palate in the T-Zone, and



Fig. 2 Benefit Direct mini-implant attaches to Hybrid Hyrax frame using specially designed ring and small fixation screw, providing tight connection with as much as 15° tolerance in insertion angle. Long intraosseous thread engages in palatal bone.**

an impression or scan was then taken and sent to the laboratory for fabrication of the appliance. Today, the appliance can be manufactured using selective laser melting (SLM).³⁶ The available metal printing powders provide high rigidity, which is especially important for expansion appliances. The process can be streamlined further by using

*TADMAN, Gunningen, Germany; www.tadman.de.

**PSM North America Inc., Indio, CA; www.psm-na.us.

computer-aided design and manufacturing (CAD/CAM) insertion guides, which facilitate safe and precise insertion of palatal mini-implants in the areas with the best bone. Moreover, these guides allow for the insertion of mini-implants and installation of the appliance in a single appointment.^{37,38}

Whether the expander is made in the laboratory or three-dimensionally printed, the temporary anchorage devices (TADs) are inserted before the appliance is bonded. This method can be called “TADs first.” An advantage of this approach is that the mini-implants can be used to anchor more than one appliance—for example, a rapid maxillary expander followed by a Beneslider** for molar distalization.³⁹ The device can easily be removed and reinstalled for modifications or repairs. Although two appointments are needed—one to insert the TADs and a second to bond the appliances—the use of an insertion guide avoids this problem. A further disadvantage is that the appliance may not fit properly if the manufacturing process is not completely accurate. This may even occur when an insertion guide is used, especially if there is a change caused by tooth eruption or movement between the original scan and the insertion appointment.

As an alternative to the TADs-first concept, Carlson and colleagues proposed placing the expansion appliance before the two to four mini-implants are inserted (as with the MSE [maxillary skeletal expander]).⁴⁰ This protocol can be called “appliance first.” A problem with this method is that the mini-implant placement sites are limited by the prefabricated nature of the appliance, which has built-in channels for miniscrew insertion. It may be possible to shift the mechanisms forward or backward to align the channels with an area of good bone, but it is unlikely that all the mini-implants will consistently end up in areas of the best bone quality, considering individual variations in patient anatomy. This is especially pertinent in the posterior molar region, where the bone height is only 1-2mm in paramedian sites.^{33,41} Additionally, because the connection between the expander and the mini-implants is not rigid, the miniscrews have some play and will tip as soon as the expander is activated.⁴²

**PSM North America Inc., Indio, CA; www.psm-na.us.

To overcome these disadvantages, Willmann and Drescher developed a new Benefit Direct system, using a mini-implant with two threads: an intraosseous thread to engage the bone and a polyaxial upper thread to engage with the expander (Fig. 2).⁴³ The upper thread interacts with a specially designed ring, which has a double inner thread that ensures a rigid connection with a tolerance of as much as 15° in the mini-implant insertion angle. This provides an angularly stable coupling mechanism between the mini-implants and the expander, while allowing placement of the mini-implants in the best available bone. The technique therefore uses the appliance-first protocol, but with a customized appliance.

Case Report

An 11-year-old female in the late mixed dentition presented with a maxillary transverse and sagittal deficiency (Fig. 3). Intraoral examination found a bilateral crossbite and a Class III malocclusion characterized by half-unit mesial molar and

TABLE 1
CEPHALOMETRIC ANALYSIS

	Pretreatment	Post-Treatment
NSBa	128.8°	128.9°
NL-NSL	5.8°	6.7°
ML-NSL	35.1°	36.7°
ML-NL	29.3°	29.9°
SNA	75.3°	80.3°
SNB	77.6°	78.0°
ANB	-2.3°	2.2°
Wits appraisal	-1.7mm	+1.9mm
U1-NL	104.0°	107.4°
L1-ML	80.6°	80.5°
U1-L1	146.0°	142.1°
Overjet	0.8mm	3.3mm
Overbite	-0.2mm	-0.4mm

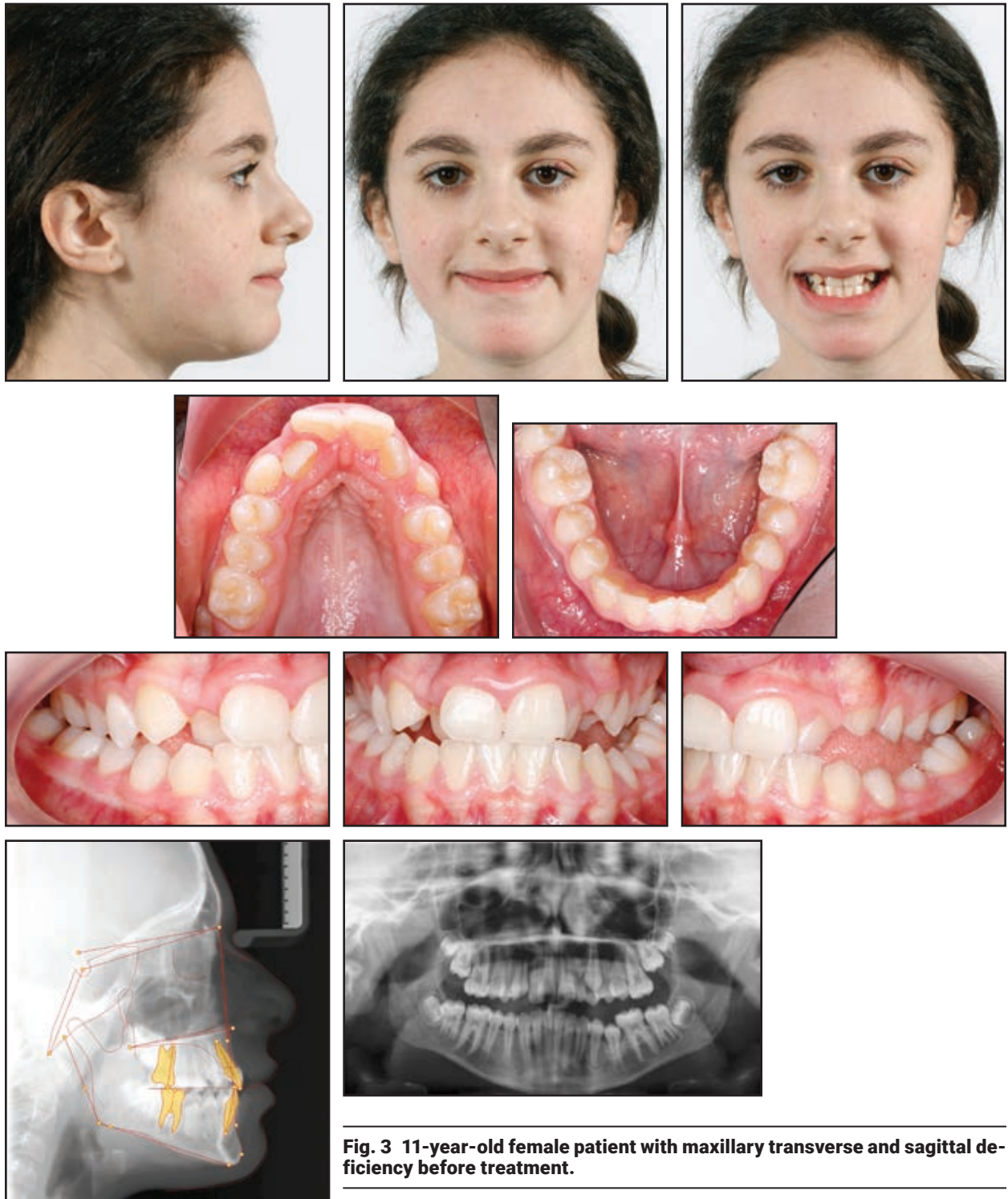

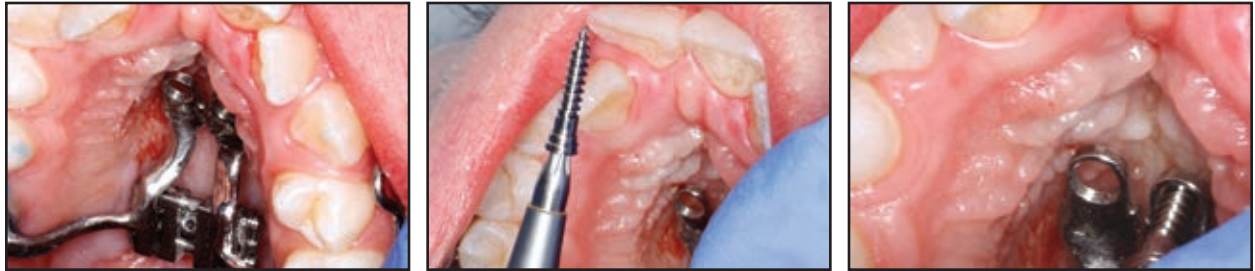


Fig. 4 Installation of Hybrid Hyrax and mini-implants following Benefit Direct protocol.

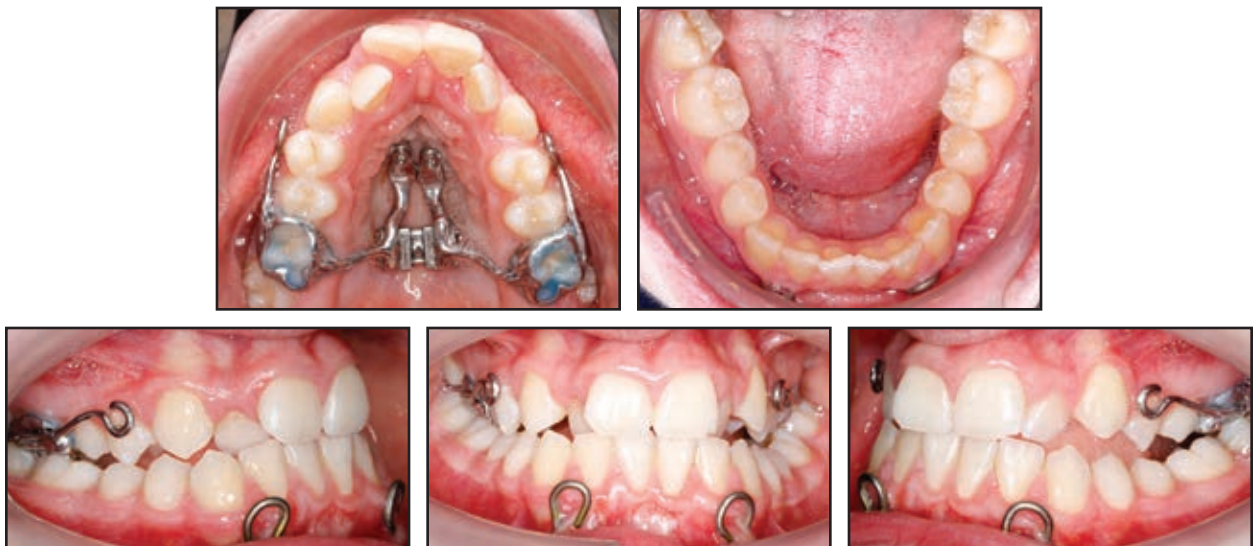

Fig. 5 Beginning of maxillary expansion and protraction.

canine relationships. The panoramic radiograph revealed a lack of space for the upper anterior teeth. Cephalometric analysis (Table 1) showed a mild skeletal Class III (Wits appraisal = -1.7mm , ANB = -2.3°) with a retrognathic maxilla (SNA = 75.3°) and slightly retrognathic mandible (SNB = 77.6°).

The relative merits, shortcomings, and risks of each potential treatment modality were explained to the patient and parents. They made an informed decision to proceed with a Hybrid Hyrax Direct mini-implant-borne maxillary expander, along with a Mentoplate*** miniplate as mandibular anchorage for Class III elastics.

A stereolithographic (STL) file of the upper scan was sent to a laboratory, where the expander

was designed by CAD. The Benefit Direct rings were planned virtually for mini-implant insertion in the T-Zone to ensure the best available bone quality.³³ The lateral cephalogram was used to plan the ideal mini-implant positions and angulations, although a CBCT may be used in complex cases. A Hybrid Hyrax framework was metal-printed, and the additional parts—a split palatal expansion screw† (thread pitch of $.2\text{mm}$), two rigid sectional wires with elastic hooks near the canines, and two rings with inner threads for the mini-implants—were mounted by laser welding. Finally, the appliance was polished for delivery.⁴⁴

The mandibular Mentoplate was inserted by an oral surgeon under local anesthesia. The Hybrid

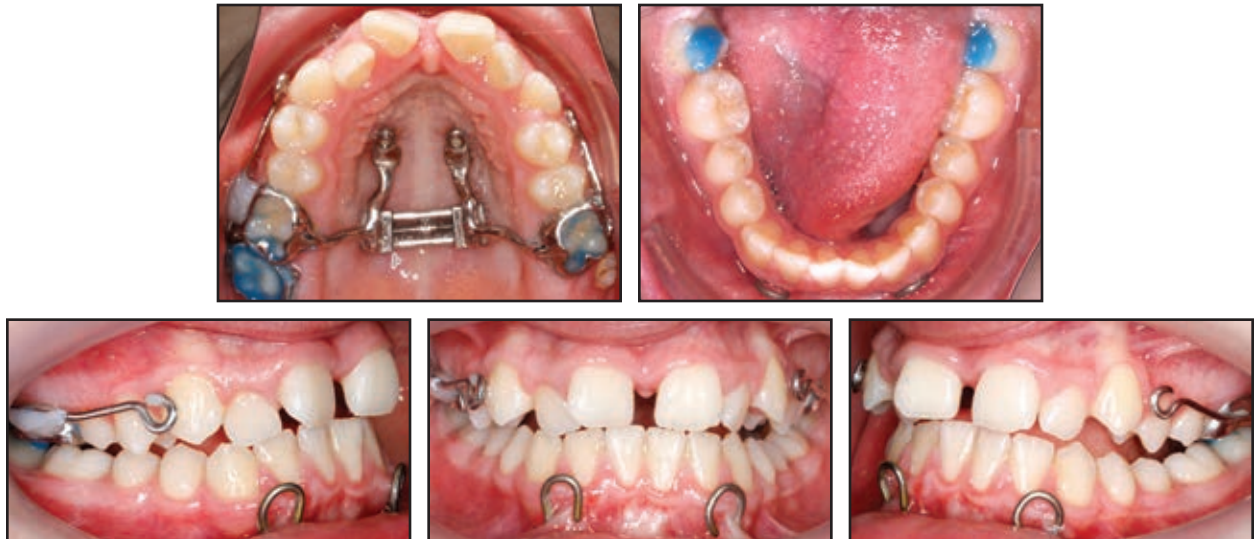

Fig. 6 After nine weeks of alternate rapid maxillary expansion and constriction (Alt-RAMEC) protocol and protraction with Class III elastics.

Hyrax expander was bonded[‡] in the orthodontic clinic, also under local anesthesia (Fig. 4). Two 2mm × 9mm mini-implants were inserted through the rings until a tight connection was achieved.

Protraction forces were applied immediately using 3.5oz Class III elastics, worn full-time. The expansion screw was activated five times per day, for a total expansion of about 1mm per day (Fig. 5). After one week of expansion, the split screw was turned in reverse for constriction. According to the Alt-RAMEC protocol, the alternating expansion and constriction were repeated for nine weeks, ending in expansion.

At the end of the Alt-RAMEC protocol, a typical midline diastema was recognizable (Fig. 6). The orthopedic treatment was finished in four months (Fig. 7). The Wits appraisal was improved from -1.7mm to +1.9mm, and the overjet from .8mm to 3.3mm (Table 1). The maxilla was displaced anteriorly, with SNA increasing by 5°—slightly more skeletal change than has been reported in the literature.^{45,46}

***PSM Medical Solutions, Gunningen, Germany; www.psm.ms.

†Forestadent GmbH, Pforzheim, Germany; www.forestadent.com.

‡G&H Orthodontics Company, Franklin, IN; www.ghorthodontics.com.

Discussion

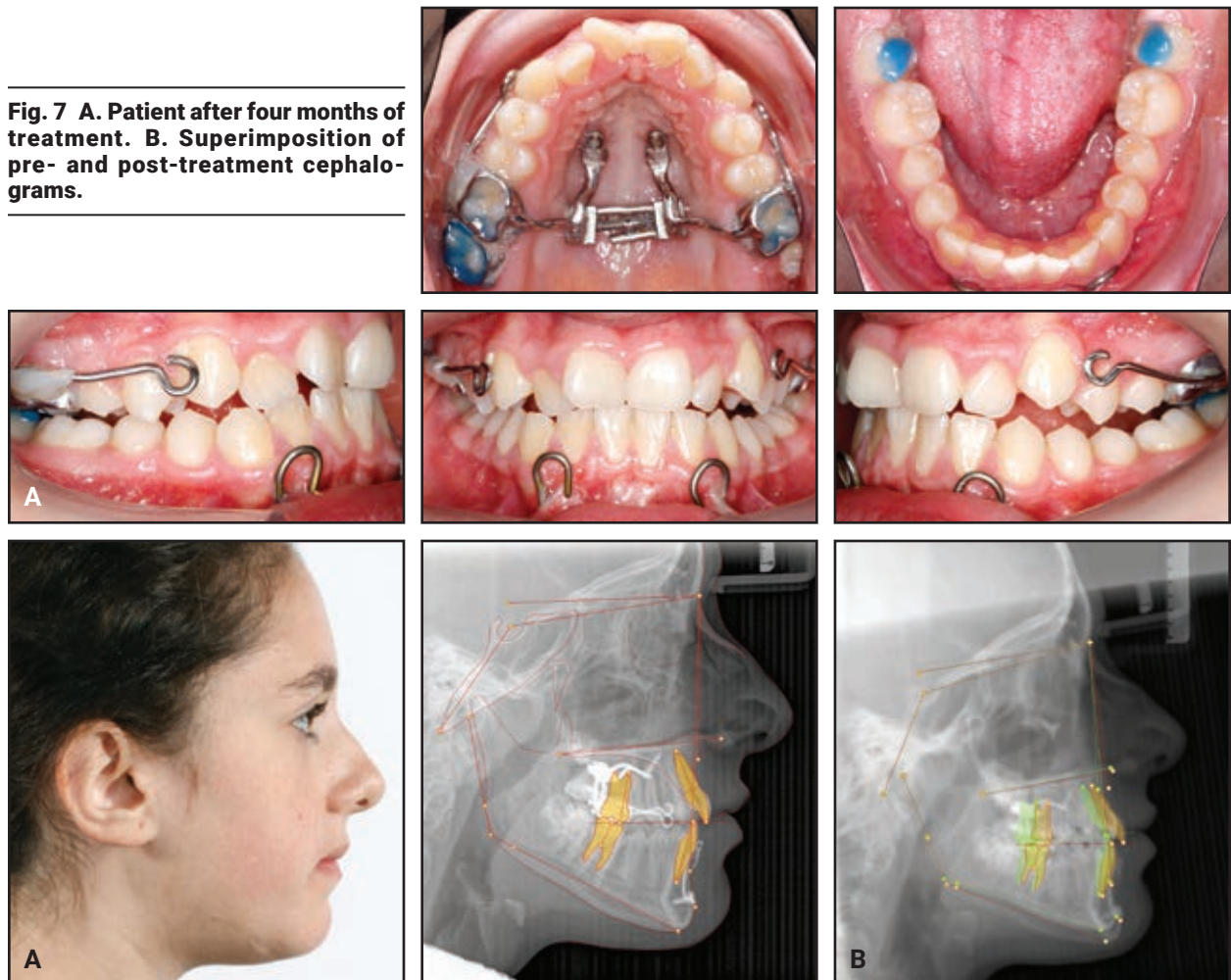
The Benefit Direct technique combines the advantages of the appliance-first and TADs-first methods. As with the prefabricated appliance-first approach, the mini-implants are inserted and the expander is installed in a single appointment. As with the TADs-first approach, the best bony insertion sites can be selected, but with no risk of misfitting the appliance and mini-implants.

Unlike prefabricated expanders, the Hybrid Hyrax is custom-manufactured, with the mini-implant thread rings positioned to align with the virtually designed mini-implants. After the expander is bonded in place, the Benefit Direct rings act as a guide for mini-implant placement. The multiaxial secondary threads provide a positive and rigid coupling with the expander, even if there is an angular discrepancy between the virtual and actual implant positions, thus avoiding unwanted tipping of the mini-implants during expansion.⁴⁰

REFERENCES

1. Kurol, J. and Berglund, L.: Longitudinal study and cost-benefit analysis of the effect of early treatment of posterior cross-bites in the primary dentition, *Eur. J. Orthod.* 14:173-179, 1992.

Fig. 7 A. Patient after four months of treatment. B. Superimposition of pre- and post-treatment cephalograms.



2. Guyer, E.C.; Ellis, E.E. III; McNamara, J.A. Jr.; and Behrents, R.G.: Components of Class III malocclusion in juveniles and adolescents, *Angle Orthod.* 56:7-30, 1986.
3. Angell, E.H.: Treatment of irregularity of the permanent or adult teeth, *Dent. Cosmos* 1:540-544, 1860.
4. Haas, A.J.: Rapid expansion of the maxillary dental arch and nasal cavity by opening the midpalatal suture, *Angle Orthod.* 31:73-90, 1961.
5. Lagravère, M.O.; Heo, G.; Major, P.W.; and Flores-Mir, C.: Meta-analysis of immediate changes with rapid maxillary expansion treatment, *J. Am. Dent. Assoc.* 137:44-53, 2006.
6. Baccetti, T.; McGill, J.S.; Franchi, L.; McNamara, J.A. Jr.; and Tollaro, I.: Skeletal effects of early treatment of Class III malocclusion with maxillary expansion and face-mask therapy, *Am. J. Orthod.* 113:333-343, 1998.
7. Kapust, A.J.; Sinclair, P.M.; and Turley, P.K.: Cephalometric effects of face mask/expansion therapy in Class III children: A comparison of three age groups, *Am. J. Orthod.* 113:204-212,

- 1998.
8. Wells, A.P.; Sarver, D.M.; and Proffit, W.R.: Long-term efficacy of reverse pull headgear therapy, *Angle Orthod.* 76:915-922, 2006.
9. Akyalcin, S.; Alexander, S.P.; Silva, R.M.; and English, J.D.: Evaluation of three-dimensional root surface changes and resorption following rapid maxillary expansion: A cone beam computed tomography investigation, *Orthod. Craniofac. Res.* 18 suppl. 1:117-126, 2015.
10. Barber, A.F. and Sims, M.R.: Rapid maxillary expansion and external root resorption in man: A scanning electron microscope study, *Am. J. Orthod.* 79:630-652, 1981.
11. Erverdi, N.; Okar, I.; Küçükkeles, N.; and Arbak, S.: A comparison of two different rapid palatal expansion techniques from the point of root resorption, *Am. J. Orthod.* 106:47-51, 1994.
12. Garib, D.G.; Henriques, J.F.; Janson, G.; De Freitas, M.R.; and Fernandes, A.Y.: Periodontal effects of rapid maxillary expansion with tooth-tissue-borne and tooth-borne expanders: A computed

- tomography evaluation, *Am. J. Orthod.* 129:749-758, 2006.
13. Carmen, M.; Marcella, P.; Giuseppe, C.; and Roberto, A.: Periodontal evaluation in patients undergoing maxillary expansion, *J. Craniofac. Surg.* 11:491-494, 2000.
14. Schuster, G.; Borel-Scherf, I.; and Schopf, P.M.: Frequency of and complications in the use of RPE appliances: Results of a survey in the Federal State of Hesse, Germany, *J. Orofac. Orthop.* 66:148-161, 2005.
15. Wilmes, B. and Drescher, D.: A miniscrew system with interchangeable abutments, *J. Clin. Orthod.* 42:574-580, 2008.
16. Wilmes, B.: Fields of application of mini-implants, in *Mini-Implants in Orthodontics: Innovative Anchorage Concepts*, ed. B. Ludwig, S. Baumgaertel, and J. Bowman, Quintessence Publishing Co., Inc., Hanover Park, IL, 2008, pp. 91-122.
17. Wilmes, B.; Nienkemper, M.; and Drescher, D.: Application and effectiveness of a mini-implant- and tooth-borne rapid palatal expansion device: The hybrid Hyrax, *World J. Orthod.* 11:323-330, 2010.
18. Garib, D.G.; Navarro, R.; Francischone, C.E.; and Oltramari, P.V.: Rapid maxillary expansion using palatal implants, *J. Clin. Orthod.* 42:665-671, 2008.
19. Lee, K.J.; Park, Y.C.; Park, J.Y.; and Hwang, W.S.: Miniscrew-assisted nonsurgical palatal expansion before orthognathic surgery for a patient with severe mandibular prognathism, *Am. J. Orthod.* 137:830-839, 2010.
20. Moon, W.; Wu, K.W.; MacGinnis, M.; Sung, J.; Chu, H.; Youssef, G.; and Machado, A.: The efficacy of maxillary protraction protocols with the micro-implant-assisted rapid palatal expander (MARPE) and the novel N2 mini-implant: A finite element study, *Prog. Orthod.* 16:16, 2015.
21. Wilmes, B.; Nienkemper, M.; Ludwig, B.; Kau, C.H.; and Drescher, D.: Early Class III treatment with a Hybrid Hyrax-Mentoplate combination, *J. Clin. Orthod.* 45:15-21, 2011.
22. Stocker, B.; Willmann, J.H.; Wilmes, B.; Vasudavan, S.; and Drescher, D.: Wear-time recording during early Class III facemask treatment using TheraMon chip technology, *Am. J. Orthod.* 150:533-540, 2016.
23. Nienkemper, M.; Wilmes, B.; Franchi, L.; and Drescher, D.: Effectiveness of maxillary protraction using a Hybrid Hyrax-facemask combination: A controlled clinical study, *Angle Orthod.* 85:764-770, 2015.
24. Ngan, P.; Wilmes, B.; Drescher, D.; Martin, C.; Weaver, B.; and Gunel, E.: Comparison of two maxillary protraction protocols: Tooth-borne versus bone-anchored protraction facemask treatment, *Prog. Orthod.* 16:26, 2015.
25. Wilmes, B.; Ngan, P.; Liou, E.J.; Franchi, L.; and Drescher, D.: Early Class III facemask treatment with the Hybrid Hyrax and Alt-RAMEC protocol, *J. Clin. Orthod.* 48:84-93, 2014.
26. Jäger, A.; Braumann, B.; Kim, C.; and Wahner, S.: Skeletal and dental effects of maxillary protraction in patients with angle Class III malocclusion: A meta-analysis, *J. Orofac. Orthop.* 62:275-284, 2001.
27. Foersch, M.; Jacobs, C.; Wriedt, S.; Hechtner, M.; and Wehrbein, H.: Effectiveness of maxillary protraction using facemask with or without maxillary expansion: A systematic review and meta-analysis, *Clin. Oral Investig.* 19:1181-1192, 2015.
28. Ngan, P. and Moon, W.: Evolution of Class III treatment in orthodontics, *Am. J. Orthod.* 148:22-36, 2015.
29. Liou, E.J.: Effective maxillary orthopedic protraction for growing Class III patients: A clinical application simulates distraction osteogenesis, *Prog. Orthod.* 6:154-171, 2005.
30. Büyükçavuş, M.H.: Alternate rapid maxillary expansion and constriction (Alt-RAMEC) protocol: A comprehensive literature review, *Turk. J. Orthod.* 32:47-51, 2019.
31. Franchi, L.; Baccetti, T.; Masucci, C.; and Defraia, E.: Early Alt-RAMEC and facial mask protocol in Class III malocclusion, *J. Clin. Orthod.* 45:601-609, 2011.
32. Almuzian, M.; McConnell, E.; Darendeliler, M.A.; Alharbi, F.; and Mohammed, H.: The effectiveness of alternating rapid maxillary expansion and constriction combined with maxillary protraction in the treatment of patients with a Class III malocclusion: A systematic review and meta-analysis, *J. Orthod.* 45:250-259, 2018.
33. Becker, K.; Unland, J.; Wilmes, B.; Tarraf, N.E.; and Drescher, D.: Is there an ideal insertion angle and position for orthodontic mini-implants in the anterior palate? A CBCT study in humans, *Am. J. Orthod.* 156:345-354, 2019.
34. Kang, S.; Lee, S.J.; Ahn, S.J.; Heo, M.S.; and Kim, T.W.: Bone thickness of the palate for orthodontic mini-implant anchorage in adults, *Am. J. Orthod.* 131:S74-S81, 2007.
35. Wilmes, B.; Ludwig, B.; Vasudavan, S.; Nienkemper, M.; and Drescher, D.: The T-Zone: Median vs. paramedian insertion of palatal mini-implants, *J. Clin. Orthod.* 50:543-551, 2016.
36. Graf, S.; Cornelis, M.A.; Hauber Gameiro, G.; and Cattaneo, P.M.: Computer-aided design and manufacture of Hyrax devices: Can we really go digital? *Am. J. Orthod.* 152:870-874, 2017.
37. De Gabriele, O.; Dallatana, G.; Riva, R.; Vasudavan, S.; and Wilmes, B.: The Easy Driver for placement of palatal mini-implants and a maxillary expander in a single appointment, *J. Clin. Orthod.* 51:728-737, 2017.
38. Wilmes, B.; Vasudavan, S.; and Drescher, D.: CAD-CAM-fabricated mini-implant insertion guides for the delivery of a distalization appliance in a single appointment, *Am. J. Orthod.* 156:148-156, 2019.
39. Nienkemper, M.; Pauls, A.; Ludwig, B.; Wilmes, B.; and Drescher, D.: Multifunctional use of palatal mini-implants, *J. Clin. Orthod.* 46:679-686, 2012.
40. Carlson, C.; Sung, J.; McComb, R.W.; Machado, A.W.; and Moon, W.: Microimplant-assisted rapid palatal expansion appliance to orthopedically correct transverse maxillary deficiency in an adult, *Am. J. Orthod.* 149:716-728, 2016.
41. Kang, S.; Lee, S.J.; Ahn, S.J.; Heo, M.S.; and Kim, T.W.: Bone thickness of the palate for orthodontic mini-implant anchorage in adults, *Am. J. Orthod.* 131:S74-S81, 2007.
42. De la Iglesia, G.; Walter, A.; de la Iglesia, F.; Winsauer, H.; and Puigdollers, A.: Stability of the anterior arm of three different Hyrax hybrid expanders: An in vitro study, *Dent. Press J. Orthod.* 23:37-45, 2018.
43. Willmann, J. and Drescher, D.: Benefit Direct: A new coupling mechanism for palatal mini-implants. Personal communication, 2019.
44. Graf, S.; Vasudavan, S.; and Wilmes, B.: CAD-CAM design and 3-dimensional printing of mini-implant retained orthodontic appliances, *Am. J. Orthod.* 154:877-882, 2018.
45. Masucci, C.; Franchi, L.; Giuntini, V.; and De Fraia, E.: Short-term effects of a modified Alt-RAMEC protocol for early treatment of Class III malocclusion: A controlled study, *Orthod. Craniofac. Res.* 17:259-269, 2014.
46. Nienkemper, M.; Wilmes, B.; Franchi, L.; and Drescher, D.: Effectiveness of maxillary protraction using a Hybrid Hyrax-facemask combination: A controlled clinical study, *Angle Orthod.* 85:764-770, 2015.